

CLINICAL REVIEW

Central venous catheters

Reston N Smith *specialty registrar in anaesthesia and intensive care medicine*¹, Jerry P Nolan *consultant in anaesthesia and intensive care medicine*²

¹North Bristol NHS Trust, Bristol, UK; ²Royal United Hospital NHS Trust, Bath, UK

Central venous catheterisation was first performed in 1929 when Werner Frossman, a German doctor, inserted a ureteric catheter into his antecubital vein. He then walked to the radiography department so that the catheter could be guided into his right ventricle using fluoroscopy. Since then, central venous access has become a mainstay of modern clinical practice. An estimated 200 000 central venous catheters were inserted in the United Kingdom in 1994,¹ and the figure is probably even higher today. Clinicians from most medical disciplines will encounter patients with these catheters. Despite the benefits of central venous lines to patients and clinicians, more than 15% of patients will have a catheter related complication.² This review will provide an overview of central venous catheters and insertion techniques, and it will consider the prevention and management of common complications.

What are central venous catheters?

A central venous catheter is a catheter with a tip that lies within the proximal third of the superior vena cava, the right atrium, or the inferior vena cava. Catheters can be inserted through a peripheral vein or a proximal central vein, most commonly the internal jugular, subclavian, or femoral vein.

What are the indications and contraindications to central venous catheterisation?

The indications for central venous catheterisation include access for giving drugs, access for extracorporeal blood circuits, and haemodynamic monitoring and interventions (box 1). Insertion of a catheter solely to measure central venous pressure is becoming less common. A systematic review found a poor correlation between central venous pressure and intravascular volume; neither a single central venous pressure value nor changes in this measurement predicted fluid responsiveness.³ The need for fluid resuscitation can be evaluated using a test of fluid responsiveness, such as the haemodynamic response to passive leg raising.⁴

Most of the contraindications to central venous catheterisation (box 2) are relative and depend on the indication for insertion.

What types of central venous catheter are available and how are they selected?

Four types of central venous catheter are available (table 1): non-tunnelled, tunnelled (fig 1A), peripherally inserted (fig 1C), and totally implantable (fig 2) catheters. Specialist non-tunnelled catheters enable interventions such as intravascular temperature control, continuous monitoring of venous blood oxygen saturation, and the introduction of other intravascular devices (such as pulmonary artery catheters and pacing wires). The catheter type is selected according to the indication for insertion and the predicted duration of use (see table 1).

How are central venous catheters inserted?

Central venous catheters are inserted by practitioners from many different medical specialties and by allied medical practitioners. Someone who is trained and experienced in the technique should be responsible for the line insertion and it should be undertaken in an environment that facilitates asepsis and adequate patient access.

At what anatomical site should I insert the central venous catheter?

The site of insertion depends on several factors: indication for insertion, predicted duration of use, previous line insertion sites (where the veins may be thrombosed or stenosed), and presence of relative contraindications. Ultrasound directed techniques for insertion are now the standard of care in the UK. The site of insertion and indication for the catheter will influence infectious, mechanical, and thrombotic complication rates. A Cochrane systematic review of central venous sites and complications concluded that, in patients with cancer and long term catheters, the risk of catheter related complications was similar for the internal jugular and subclavian routes.⁵ For short term central venous catheters, this review concluded that the risk of catheter colonisation (14.2% v 2.2%; relative risk 6.43, 95% confidence interval 1.95 to 21.2) and thrombotic

Summary points

- A wide variety of central venous catheters are used
- Complications related to central venous catheters are common and may cause serious morbidity and mortality
- Several strategies can reduce central venous catheter related morbidity; these are implemented at catheter insertion and for the duration of its use
- Peripherally inserted central catheters have the same, or even higher, rate of complications as other central venous catheters

Sources and selection criteria

We searched the Cochrane Database of Systematic Reviews, Medline, Embase, and Clinical Evidence online. Search terms included central venous catheter, peripherally inserted central catheter, and complication. The reference lists of relevant studies were hand searched to identify other studies of interest. We also consulted relevant reports and national guidelines.

Box 1 Indications for central venous catheterisation*Access for drugs*

- Infusion of irritant drugs—for example, chemotherapy
- Total parenteral nutrition
- Poor peripheral access
- Long term administration of drugs, such as antibiotics

Access for extracorporeal blood circuits

- Renal replacement therapy
- Plasma exchange

Monitoring or interventions

- Central venous pressure
- Central venous blood oxygen saturation
- Pulmonary artery pressure
- Temporary transvenous pacing
- Targeted temperature management
- Repeated blood sampling

Box 2 Potential contraindications to central venous catheterisation

- Coagulopathy
- Thrombocytopenia
- Ipsilateral haemothorax or pneumothorax
- Vessel thrombosis, stenosis, or disruption
- Infection overlying insertion site
- Ipsilateral indwelling central vascular devices

complications (21.6% v 1.9%; 11.53, 2.8 to 47.5) is higher for the femoral route than for the subclavian one.⁵

In contrast, a meta-analysis documented no difference in the risk of infectious complications between the internal jugular, subclavian, and femoral routes.⁶ The ease of imaging of the internal jugular vein compared with the subclavian vein has made the first route more popular for short term access. A Cochrane review found that for short term access, for haemodialysis, the femoral and internal jugular sites have similar risks of catheter related complications, although the internal jugular route is associated with a higher rate of mechanical complications.⁵ Recent Kidney Disease Improving Global Outcomes (KDIGO) guidelines recommend, in order of preference, the right internal jugular, femoral, left internal jugular, and subclavian veins for insertion of a short term dialysis catheter.⁷

Technique of inserting a cannula into the internal jugular vein

Box 3 describes in detail the technique for inserting a central venous catheter (fig 3↓).

Skin preparation

The skin is prepared with a solution of 2% chlorhexidine in 70% isopropyl alcohol.⁹ A meta-analysis found a reduction in catheter related infections when chlorhexidine is used instead of povidone-iodine.¹⁰ However, a systematic review has highlighted that many of the studies on this topic have compared chlorhexidine in alcohol with aqueous povidone-iodine.¹¹ The immediate action of alcohol might combine with the more persistent effect of chlorhexidine to produce optimal antisepsis.

Ultrasound guidance

National Institute for Health and Care Excellence (NICE) guidelines recommend using ultrasound guidance for the elective insertion of central venous catheters into the internal jugular

Box 3 Technique of inserting a central venous catheter into the internal jugular vein

Explain the procedure to the patient and obtain written informed consent

Continuously monitor with pulse oximetry (for arterial blood oxygen saturation) and electrocardiography (for early identification of arrhythmias induced by the wire or catheter)

Using ultrasound, assess the anatomical location and patency of the internal jugular vein (fig 3A and B)

Place the patient in the Trendelenburg position, with the head slightly rotated to the contralateral side; excess rotation will compress the internal jugular vein, compromising the ability to cannulate the vessel

Use a strict aseptic technique. After thorough hand washing, put on a sterile gown, gloves, mask, and hat and place a sterile full body drape over the patient. Lay out all equipment on a trolley. Use a sterile ultrasound probe cover and sterile conductive jelly

Guided by real time ultrasound imaging (ideally, using both in-plane and out of plane views), insert a needle mounted on a syringe into the internal jugular vein (fig 3C)

Once blood is freely aspirated, set aside the ultrasound probe and remove the syringe from the needle. Blood flow from the needle should be non-pulsatile, but non-pulsatile blood flow does not exclude arterial penetration

Advance the guide wire through the needle into the vessel, remove the needle, and then confirm the guide wire position with ultrasound imaging (fig 3D). If the guide wire position remains uncertain, insert a short narrow cannula over the wire and into the vessel. Connect the cannula to a transducer system to confirm a venous pressure waveform. Reintroduce the wire through the cannula and then remove the cannula

If a narrow bore cannula is placed in an artery, remove it and apply pressure. Options for dealing with a large bore catheter introduced into an artery are covered in a recent review.⁹ Make a small incision with a scalpel to facilitate the passage of the dilator. Pass the dilator over the wire to a depth a little greater than the predicted vessel depth; this reduces the risk of vessel injury. Maintain control of both the guide wire and dilator at all times

Remove the dilator. Pass the central venous catheter on to the guide wire and withdraw the guide wire until it protrudes from the end of the catheter

Advance the catheter into the vessel and remove the guide wire

Using ultrasound, confirm correct placement of the catheter in the vein

Secure the catheter and place a dressing over the insertion site

Obtain a chest radiograph to confirm the location of the catheter tip.

vein in adults and children.¹² A meta-analysis indicates that ultrasound guided placement results in lower failure rates, reduced complications, and faster access compared with the landmark technique.¹³ Real time imaging of needle passage into the vessel can be performed out of plane (vessel imaged in the transverse plane) or in-plane (vessel imaged in the longitudinal plane). An international expert consensus group concluded that, although no one technique is better than another, a combination of the two may be optimal.¹⁴ The in-plane technique is technically more challenging but enables the position of the tip of the thin walled needle (or cannula) and the wire to be identified precisely (for example, inadvertent penetration of the posterior wall of the vein will be seen clearly). Although ultrasound imaging of the internal jugular and femoral veins is much easier than imaging of the subclavian vein (the view is obscured by the clavicle), ultrasound guided catheterisation of the subclavian vein is possible with the use of a slightly more lateral approach (initially entering the infraclavicular axillary vein).^{15 16}

What is the optimal location for the tip of the central venous catheter?

Incorrect placement of the catheter tip increases mechanical and thrombotic complications, but the ideal location of the catheter tip depends on the indications for catheterisation and the site of insertion. No single catheter tip position is ideal for all patients. Patients with cancer are at high risk for developing thrombosis. To reduce rates of thrombosis related to long term catheters in these patients, the catheter tip should lie at the junction of the superior vena cava and right atrium, which is below the pericardial reflection and lower than that recommended for other patients.¹⁷ In other patients, expert opinion suggests that the tip should lie parallel to the wall of a large central vein outside of the pericardial reflection.⁸ This reduces the risk of perforation and the risk of cardiac tamponade if perforation occurs. When viewed on a chest radiograph, the catheter tip should be above the level of the carina, which ensures placement above the

pericardial sac.¹⁸ High placement of the catheter tip in the superior vena cava increases the risk of thrombosis.⁸

Several techniques can help position the tip correctly during insertion. For short term catheters the insertion depth can be estimated from measurements taken before or during insertion or derived from formulae; alternatively, invasive techniques such as right atrial electrocardiography and transoesophageal echocardiography can be used. Long term catheters are often inserted under radiographic guidance and the catheter tip positioned dynamically.

What are the complications of central venous catheterisation?

Complications are divided into immediate and delayed, then subdivided into mechanical, embolic, and infectious (table 2).¹ Strict attention to insertion technique and correct line-tip positioning reduces the risks of many of the mechanical and embolic complications of catheter insertion. Complications such as air embolism may occur at any point during the lifetime of the line and can be related to poor technique during line insertion, use of the line, or line removal.

Infective complications

The mean central venous catheter bloodstream infection (CVC-BSI) rate documented in a large study of 215 UK intensive care units (ICUs) that submitted data for up to 20 months was 2.0 per 1000 central venous catheter days.¹⁹ In a 2011 UK national point prevalence survey on healthcare associated infections and antimicrobial use, 40% of primary blood stream infections were related to a central venous catheter.²⁰ An American case-control study of critically ill patients found that nosocomial blood stream infection was associated with increased mortality, length of stay in hospital and intensive care, and economic burden.²¹

What are the clinical signs of line infection?

Clinical signs are unreliable. Fever is the most sensitive clinical finding but is not specific. The presence of inflammation or pus at the catheter exit site is more specific but less sensitive. Consider a diagnosis of CVC-BSI in patients with signs of systemic infection in the absence of another identifiable source or who develop signs of systemic infection after flushing of the line. Box 4 details the laboratory diagnosis of this infection. Maintain a high index of suspicion when blood cultures are positive for organisms associated with central venous catheter infection: *Staphylococcus aureus*, coagulase negative staphylococci, or candida with no other obvious source for bacteraemia.²²

What are the common causes of central venous catheter infection or colonisation?

Colonisation occurs on the endoluminal or extraluminal surface of the line. Extraluminal colonisation occurs early after line insertion—micro-organisms from the skin colonise the line during insertion or migrate along the catheter tract. Less often, extraluminal colonisation occurs by haematogenous seeding of infection from a distant site. Endoluminal contamination occurs late and is caused by manipulation of the catheter hubs during interventions or more rarely from contamination of infusate. The organisms causing catheter colonisation and infection are most commonly coagulase negative staphylococci (particularly *S epidermidis*), enterococci, *S aureus*, and *Candida* spp.

It is not always possible to prove that the central line is the source of infection. For the purposes of research and epidemiological surveillance, two terms are used to describe CVC-BSI (box 4): catheter related bloodstream infection and central line associated bloodstream infection.

Establishing the criteria for catheter related bloodstream infection requires specialist microbiological testing or line removal (box 4). It is often not possible to remove the catheter or gain access to quantitative blood cultures. Unlike catheter related bloodstream infection, central line associated bloodstream infection does not require direct microbiological evidence of line contamination to identify the catheter as the cause, so this diagnosis often overestimates the rate of catheter infection.

Do antimicrobial or antiseptic impregnated catheters reduce the rate of CVC-BSI?

Impregnating the surface of the catheter with antiseptic or antimicrobial substances (such as chlorhexidine and silver sulfadiazine) reduces CVC-BSI. A Cochrane review of the effectiveness of this approach for reducing CVC-BSI in adults included 56 studies and 16 512 catheters with 11 different types of impregnation, bonding, or coating.²³ Catheter impregnation reduced the risk of catheter related bloodstream infections and catheter colonisation. The rate of sepsis or all cause mortality was not reduced, and the benefit of impregnation varied with the clinical setting, being most beneficial in the ICU. The draft epic 3 guidelines recommend that impregnated lines should be used only in patients who are expected to have a catheter in place for more than five days and in units where the CVC-BSI rate remains high despite implementation of a package to reduce it.²⁴

Do multi-lumen central venous catheters increase the risk of infection?

A meta-analysis of all the available evidence concluded that multi-lumen catheters may be associated with a slightly higher risk of infection than single lumen ones. However, when only high quality studies (which controlled for patient differences) were considered, there was no increase in infection risk.²⁵ Therefore, insert a catheter with the minimum number of lumens considered essential for patient care.²⁴

Does antibiotic prophylaxis reduce infection rates?

A Cochrane review concluded that prophylactic vancomycin or teicoplanin given before insertion of a tunnelled catheter in patients with cancer did not significantly reduce the number of early Gram positive line infections.²⁶ A review of 16 randomised controlled trials found insufficient evidence to recommend the routine use of antibiotic lock solutions for preventing CVC-BSI.²⁷

Do not use prophylactic antibiotics before line insertion, antibiotic lock solutions, or antibiotic ointments applied to the insertion site. These strategies do not reduce rates of CVC-BSI and, theoretically, routine use could alter patterns of antimicrobial resistance.

What interventions will reduce infective complications?

There is no evidence that the type of dressing placed over the insertion site influences the rate of catheter related infection. A Cochrane review of two small studies found no difference between gauze and tape versus transparent polyurethane dressings.²⁸ The draft epic 3 national evidence based guidelines for preventing healthcare associated infections recommend use of a transparent semipermeable polyurethane dressing.²⁴ If there is bleeding or excessive moisture, a sterile gauze dressing can be used initially and replaced with a transparent dressing when possible. The dressing is not changed unless it is dislodged or there is pooling of fluid or blood under the dressing.

Intraluminal contamination of the catheter occurs through its access sites, so more frequent access through the catheter hub increases the likelihood of microbial contamination. Decontaminate the catheter hub or access port with 2% chlorhexidine in 70% alcohol before and after access.

The catheter can be exchanged over a guide wire or inserted at a different site. Evidence does not support the routine exchange of central venous catheters. A systematic review of exchange techniques showed that guide wire exchange was associated with a reduction in mechanical complications but also an increase in the frequency of catheter colonisation and CVC-BSI; however, none of these associations were significant.²⁹ Four trials comparing prophylactic catheter exchange at three days versus exchange at seven days, or as needed, found no differences in rates of catheter colonisation or CVC-BSI. Do not guide wire exchange a new catheter through a line that is known to be infected; however, if the risk of mechanical complications related to line insertion is high, and the current catheter is not infected, guide wire replacement is reasonable.

A meta-analysis has shown that daily bathing of ICU patients with chlorhexidine gluconate reduces healthcare related infection and central line associated bloodstream infection,³⁰ but in our experience this is not common practice in the UK.

The duration that a line should remain in situ before elective exchange or removal is not known. Review the ongoing

Box 4 Criteria for the diagnosis of central venous catheter related infections (Centers for Disease Control and Prevention (CDC) definitions)*Catheter related bloodstream infection**

- Presence of an intravascular device
- Evidence of systemic infection—pyrexia, tachycardia, or hypotension in the absence of another source of infection
- Laboratory evidence that the catheter is the source:
 - If the catheter has been removed: quantitative or semiquantitative culture of the catheter
 - If the catheter remains in situ: quantitative paired blood cultures (peripheral cultures and cultures drawn from central catheter) or differential time to positivity of paired blood cultures

*Central line associated bloodstream infection**

- Evidence of systemic infection
- Central line has been in situ during the 48 hours before blood being cultured
- Laboratory confirmed bloodstream infection on peripheral blood culture
- No evidence of infection from another site

*All criteria needed for a diagnosis.

requirement for a central line daily. Consider removal if it is no longer essential, the catheter is non-functioning, or there is associated infection or thrombosis. The decision to remove the line is made in the context of its clinical indication, the difficulty of establishing further central venous access, and the risk of it remaining in situ.

System based strategies to reduce rates of CVC-BSI

In a collaborative cohort study, implementation of a bundle of evidence based interventions significantly reduced CVC-BSI in 103 ICUs in Michigan, US; the benefit persisted for 18 months.³¹ The interventions comprised:

- Hand washing
- Using full barrier precautions during insertion
- Cleaning the skin with chlorhexidine
- Avoiding the femoral site if possible
- Removing unnecessary catheters.

The ICU staff also implemented a daily goals sheet to improve communication between clinicians, an intervention to reduce the incidence of ventilator associated pneumonia, and a comprehensive safety programme to improve the safety culture. The reduction in CVC-BSI was maintained 36 months after implementation of the interventions.³² Using a similar approach, in the UK, a two year stepped intervention programme (Matching Michigan) was associated with a marked reduction in rates of CVC-BSI in 196 adult ICUs (mean 3.7 CVC-BSIs/1000 catheter patient days in the first cluster to mean 1.48 CVC-BSIs/1000 catheter patient days for all clusters combined; $P < 0.0001$).¹⁹

What are the risks and complications of central venous catheter related thrombosis?

The presence of a central venous catheter is an independent risk factor for venous thromboembolism,³³ but many of the indications for placement of a catheter are also risk factors for the development of thromboembolism (box 5).

Catheter related thrombosis can be symptomatic or asymptomatic. The thrombus is present on the catheter itself or on the vessel wall. Symptomatic thrombosis is diagnosed with duplex ultrasonography or contrast venography. It is associated with symptoms and signs such as swelling of the affected limb, discomfort, erythema, low grade fever, and dilation of collateral veins. Asymptomatic thrombosis is diagnosed on screening or coincidental imaging in the absence of associated signs or

symptoms. Asymptomatic thrombosis may present with line occlusion. Reported rates of catheter related thrombosis vary widely—from 2% to 67%; the incidence of symptomatic catheter related thrombosis is 0-28%.³⁴

Potential complications of catheter related thrombosis are thromboembolism, interruption of venous flow, line infection, and catheter occlusion. The thrombus may embolise to the right heart or pulmonary circulation. The reported incidence of symptomatic pulmonary embolism is 0-17% in patients with catheter related thrombosis.³⁴ The thrombus may act as a site for bacterial growth.

The post-thrombotic syndrome is well described in deep vein thrombosis unrelated to central venous catheterisation and is characterised by venous hypertension, swelling, and pain. There is little evidence to establish the risk of the post-thrombotic syndrome and recurrent thrombosis after catheter related thrombosis.

How can catheter related thrombosis be prevented?

The use of prophylactic anticoagulants to prevent catheter related thrombosis has been studied extensively. A Cochrane review of anticoagulation in patients with cancer and a central venous catheter found no significant effect of low dose vitamin K antagonists or low dose unfractionated heparin on mortality, infection, bleeding, or thrombocytopenia.³⁵

A meta-analysis of 15 studies (10 of patients with cancer and five of patients receiving long term parenteral nutrition) found that anticoagulant prophylaxis reduced the risk of all catheter related thromboses (symptomatic and asymptomatic) but not the rate of pulmonary embolism or mortality.³⁶

On the basis of these data, use of anticoagulant prophylaxis to prevent catheter related thrombosis is not recommended.¹⁷

How should I treat catheter related thrombosis?

Treatment of catheter related thrombosis includes prevention of complications and management of the central venous catheter. Therapeutic anticoagulation reduces the risk of embolic complications and of the post-thrombotic syndrome, and it prevents recurrent thrombosis. Consider anticoagulation in any patient with a demonstrable deep vein thrombosis on imaging. International evidence based guidelines recommend that patients with cancer and symptomatic catheter related thrombosis are given anticoagulants for three months—low molecular weight heparin or vitamin K antagonists.¹⁷ Thrombolytic treatment has the potential to restore venous patency and catheter patency.

Box 5 Risk factors for central venous catheter related thrombosis*Patient related factors*

- Hypercoagulable state (acute or chronic)
- Cancer
- Cancer treatment
- Age
- Previous deep vein thrombosis

Device related factors

- Line material
- Number of lumens (catheter diameter)
- Position of catheter tip
- Presence of line infection
- Line insertion site

Although a Cochrane review found inadequate evidence to support or refute the use of thrombolysis to restore catheter patency, this strategy is commonly used.³⁷ If the catheter is positioned correctly, functioning, and not infected, it may be left in situ. Remove the catheter if distal limb swelling is not resolving.

Peripherally inserted central catheters

Peripherally inserted central catheters (fig 1C) provide intravenous access for long term antibiotics—particularly for patients with difficult intravenous access and for those receiving intravenous antibiotics in the community—and for parenteral nutrition, chemotherapy, blood products, and blood sampling. They can be left in situ for several months. Their recent popularity probably reflects improved access to this technique delivered at the bedside by dedicated vascular access teams, as well as a belief that these lines combine the advantages of central access with a reduction in the risks associated with traditional central venous catheters. Although these lines are associated with fewer mechanical complications at insertion,³⁸ a recent systematic review and meta-analysis of 64 studies found that the rates of upper extremity deep vein thrombosis are higher with peripherally inserted central catheters than with central venous catheters.³⁹ This increase in risk is greatest in critically ill patients and those with cancer.

Two further reviews comparing complication rates with these two types of catheter have challenged the established belief that peripheral lines are safer.^{40 41} The authors of one review concluded that malpositioning of the catheter tip, thrombophlebitis, and catheter dysfunction were more common with these lines than with central venous catheters,⁴⁰ and the authors of both reviews conclude that there is no difference in rates of infection associated with either line in hospital inpatients.

Although often considered a safe and convenient solution to difficult intravenous access in the long term, the risks and benefits of peripherally inserted lines must be considered carefully before insertion.

Caring for central venous catheters

Responsibility for the daily care of long term central lines is often delegated to patients and their relatives or carers. Meticulous attention to detail in care will reduce the likelihood of a line related complication. The sterile, transparent, semipermeable dressing is removed weekly, or sooner if it is soiled or not intact. Before replacing the dressing, clean the insertion site with 2% chlorhexidine in 70% alcohol²⁴. If the

line is not used regularly, aspirate and flush all lumens weekly. To reduce the risk of line infection, patients are advised to shower and not bathe (if bathing, do not submerge the line in water). Swimming is not recommended because the line will be completely submerged. Vigorous physical activity involving the upper body may cause the line to be displaced and should be avoided. Patients with long term central venous catheters with implanted ports are free from all of these restrictions.

Contributors: All authors helped plan and write this review. JPN is guarantor.

Competing interests: We have read and understood the BMJ Group policy on declaration of interests and declare the following interests: None.

Provenance and peer review: Commissioned; externally peer reviewed.

- 1 Waghorn DJ. Intravascular device-associated systemic infections: a 2 year analysis of cases in a district general hospital. *J Hosp Infect* 1994;28:91-101.
- 2 McGee DC, Gould MK. Preventing complications of central venous catheterization. *N Engl J Med* 2003;348:1123-33.
- 3 Marik PE, Baram M, Vahid B. Does central venous pressure predict fluid responsiveness? A systematic review of the literature and the tale of seven mares. *Chest* 2008;134:172-8.
- 4 Monet X, Teboul J-L. Passive leg raising. *Intensive Care Med* 2008;34:659-63.
- 5 Ge X, Cavallazzi R, Li C, Pan SM, Wang YW, Wang FL. Central venous access sites for the prevention of venous thrombosis, stenosis and infection. *Cochrane Database Syst Rev* 2012;3:CD004084.
- 6 Marik PE, Flemmer M, Harrison W. The risk of catheter-related bloodstream infection with femoral venous catheters as compared to subclavian and internal jugular venous catheters: a systematic review of the literature and meta-analysis. *Crit Care Med* 2012;40:2479-85.
- 7 Kellum JA. KDIGO clinical practice guideline for acute kidney injury. *Kidney Int Suppl* 2012;2(1).
- 8 Gibson F, Bodenham A. Misplaced central venous catheters: applied anatomy and practical management. *Br J Anaesth* 2013;110:333-46.
- 9 Pratt RJ, Pellowe CM, Wilson JA, Loveday HP, Harper PJ, Jones SR, et al. epic2: National evidence-based guidelines for preventing healthcare-associated infections in NHS hospitals in England. *J Hosp Infect* 2007;65(suppl 1):S1-64.
- 10 Chaiyakunapruk N, Veenstra DL, Lipsky BA, Saint S. Chlorhexidine compared with povidone-iodine solution for vascular catheter-site care: a meta-analysis. *Ann Intern Med* 2002;136:792-801.
- 11 Maiwald M, Chan ES. The forgotten role of alcohol: a systematic review and meta-analysis of the clinical efficacy and perceived role of chlorhexidine in skin antiseptics. *PLoS One* 2012;7:e44277.
- 12 National Institute for Health and Care Excellence. Guidance on the use of ultrasound locating devices for placing central venous catheters. TA49. 2002. <http://guidance.nice.org.uk/TA49>.
- 13 Hind D, Calvert N, McWilliams R, Davidson A, Paisley S, Beverley C, et al. Ultrasonic locating devices for central venous cannulation: meta-analysis. *BMJ* 2003;327:361.
- 14 Lamperti M, Bodenham AR, Pittiruti M, et al. International evidence-based recommendations on ultrasound-guided vascular access. *Intensive Care Med* 2012;38:1105-17.
- 15 Sharma A, Bodenham AR, Mallick A. Ultrasound-guided infraclavicular axillary vein cannulation for central venous access. *Br J Anaesth* 2004;93:188-92.
- 16 Fragou M, Gravvanis A, Dimitriou V, Papalois A, Kouraklis G, Karabibis A, et al. Real-time ultrasound-guided subclavian vein cannulation versus the landmark method in critical care patients: a prospective randomized study. *Crit Care Med* 2011;39:1607-12.
- 17 Debourdeau P, Farge D, Beckers M, Baglin C, Bauersachs RM, Brenner B, et al. International clinical practice guidelines for the treatment and prophylaxis of thrombosis associated with central venous catheters in patients with cancer. *J Thromb Haemost* 2013;11:71-80.
- 18 Albrecht K, Nave H, Breitmeier D, Panning B, Troger HD. Applied anatomy of the superior vena cava—the carina as a landmark to guide central venous catheter placement. *Br J Anaesth* 2004;92:75-7.

Additional educational resources*Resources for healthcare professionals*

Ortega R, Song M, Hansen CJ, Barash P. Ultrasound-guided internal jugular vein cannulation. *N Engl J Med* 2010;362:e57. Video showing insertion of an internal jugular central venous catheter

University of West London. Epic 3 national evidence based guidelines for preventing healthcare associated infections. 2013. www.uwl.ac.uk/sites/default/files/Academic-schools/College-of-Nursing-Midwifery-and-Healthcare/Web/Epic3/epic3_Consultation_Draft.pdf

Resources for patients

New South Wales Government, Australia (<http://intensivecare.hsnet.nsw.gov.au/central-venous-lines>)—Patient information on central venous lines

Macmillan (www.macmillan.org.uk/Cancerinformation/Cancertreatment/Treatmenttypes/Chemotherapy/Linesports/Centrallines.aspx)—Patient information on tunnelled central lines

Christie NHS Foundation Trust (www.christie.nhs.uk/booklets/10.pdf)—A guide for patients and their carers on the care of central venous catheters

Questions for future research

Do peripherally inserted central catheters have a higher rate of complications than traditional central venous catheters?

Should routine screening be used to detect asymptomatic catheter related thrombosis?

What is the optimal way to manage asymptomatic catheter related thrombosis?

What is the optimal technique for ultrasound directed subclavian vein catheterisation?

- 19 Bion J, Richardson A, Hibbert P, Beer J, Abrusci T, McCutcheon M, et al. "Matching Michigan": a 2-year stepped interventional programme to minimise central venous catheter-blood stream infections in intensive care units in England. *BMJ Qual Saf* 2013;22:110-23.
- 20 Hopkins S, Shaw K, Simpson L. English national point prevalence survey on healthcare associated infections and antimicrobial use, 2011: preliminary data. Health Protection Agency, 2012. www.hpa.org.uk/webc/hpawebfile/hpaweb_c/1317134304594.
- 21 Pittet D, Tarara D, Wenzel RP. Nosocomial bloodstream infection in critically ill patients. Excess length of stay, extra costs, and attributable mortality. *JAMA* 1994;271:1598-601.
- 22 Mermel LA, Alon M, Bouza E, Craven DE, Flynn P, O'Grady NP, et al. Clinical practice guidelines for the diagnosis and management of intravascular catheter-related infection: 2009 update by the Infectious Diseases Society of America. *Clin Infect Dis* 2009;49:1-45.
- 23 Lai NM, Chaiyakunapruk N, Lai NA, O'Riordan E, Pau WSC, Saint S. Catheter impregnation, coating or bonding for reducing central venous catheter-related infections in adults. *Cochrane Database Syst Rev* 2013;6:CD007878.
- 24 Loveday HP, Wilson JA, Pratt RJ, Golsorkhi M, Tingle A, Bak A, et al. epic3 National evidence-based guidelines for preventing healthcare-associated infections in NHS hospitals in England. 2013. www.uwl.ac.uk/sites/default/files/Academic-schools/College-of-Nursing-Midwifery-and-Healthcare/Web/Epic3/epic3_Consultation_Draft.pdf.
- 25 Dezfulian C, Lavelle J, Nallamothu BK, Kaufman SR, Saint S. Rates of infection for single-lumen versus multilumen central venous catheters: a meta-analysis. *Crit Care Med* 2003;31:2385-90.
- 26 Van de Wetering MD, van Woensel JB. Prophylactic antibiotics for preventing early central venous catheter Gram positive infections in oncology patients. *Cochrane Database Syst Rev* 2007;1:CD003295.
- 27 Snaterse M, Ruger W, Scholte Op Reimer WJ, Lucas C. Antibiotic-based catheter lock solutions for prevention of catheter-related bloodstream infection: a systematic review of randomised controlled trials. *J Hosp Infect* 2010;75:1-11.
- 28 Webster J, Gillies D, O'Riordan E, Sherriff KL, Rickard CM. Gauze and tape and transparent polyurethane dressings for central venous catheters. *Cochrane Database Syst Rev* 2011;11:CD003827.
- 29 Cook D, Randolph A, Kernerman P, Cupido C, King D, Soukup C, et al. Central venous catheter replacement strategies: a systematic review of the literature. *Crit Care Med* 1997;25:1417-24.
- 30 O'Horo JC, Silva GL, Munoz-Price LS, Safdar N. The efficacy of daily bathing with chlorhexidine for reducing healthcare-associated bloodstream infections: a meta-analysis. *Infect Control Hosp Epidemiol* 2012;33:257-67.
- 31 Pronovost P, Needham D, Berenholtz S, Sinopoli D, Chu H, Cosgrove S, et al. An intervention to decrease catheter-related bloodstream infections in the ICU. *N Engl J Med* 2006;355:2725-32.
- 32 Pronovost PJ, Goeschel CA, Colantuoni E, Watson S, Lubomski LH, Berenholtz SM, et al. Sustaining reductions in catheter related bloodstream infections in Michigan intensive care units: observational study. *BMJ* 2010;340:c309.
- 33 Shivakumar SP, Anderson DR, Couban S. Catheter-associated thrombosis in patients with malignancy. *J Clin Oncol* 2009;27:4858-64.
- 34 Rooden CJ, Tesselaar ME, Osanto S, Rosendaal FR, Huisman MV. Deep vein thrombosis associated with central venous catheters—a review. *J Thromb Haemostas* 2005;3:2409-19.
- 35 Aki EA, Vasireddi SR, Gunukula S, Yosico VED, Barba M, Sperati F, et al. Anticoagulation for patients with cancer and central venous catheters. *Cochrane Database Syst Rev* 2011;4:CD006468.
- 36 Kirkpatrick A, Rathbun S, Whitsett T, Raskob G. Prevention of central venous catheter-associated thrombosis: a meta-analysis. *Am J Med* 2007;120:901e1-13.
- 37 Van Miert C, Hill R, Jones L. Interventions for restoring patency of occluded central venous catheter lumens. *Cochrane Database Syst Rev* 2012;4:CD007119.
- 38 Gallieni M, Pittiruti M, Biffi R. Vascular access in oncology patients. *CA Cancer J Clin* 2008;58:323-46.
- 39 Chopra V, Anand S, Hickner A, Buist M, Rogers MAM, Saint S, et al. Risk of venous thromboembolism associated with peripherally inserted central catheters: a systematic review and meta-analysis. *Lancet* 2013;382:311-25.
- 40 Pikwer A, Akeson J, Lindgren S. Complications associated with peripheral or central routes for central venous cannulation. *Anaesthesia* 2012;67:65-71.
- 41 Chopra V, Anand S, Krein SL, Chenoweth C, Saint S. Bloodstream infection, venous thrombosis, and peripherally inserted central catheters: reappraising the evidence. *Am J Med* 2012;125:733-41.

Cite this as: *BMJ* 2013;347:f6570

© BMJ Publishing Group Ltd 2013

Tables

Table 1 | Types of central venous catheter

Type of line	Sites of insertion	Expected duration	Comments	Examples of use
Non-tunnelled	Internal jugular vein, subclavian vein, axillary vein, femoral vein	Short term (several days to 3 weeks)	Line and ports protrude directly from entry site; multi-lumen line	Difficult intravenous access; infusion of irritant drugs, vasopressors, inotropes; short term total parenteral nutrition
Peripherally inserted	Basilic vein, cephalic vein, brachial vein	Medium term (weeks to months)	Line and ports protrude directly from entry site; uncuffed; single, dual, or triple lumen; requires adequate peripheral venous access	Difficult intravenous access; blood sampling; medium term drug administration (for example, antibiotics); administration of irritant drugs (such as chemotherapy); total parenteral nutrition
Tunnelled (for example, Hickmann, Groshong)	Internal jugular vein, subclavian vein	Long term (months to years)	Subcutaneous tunnel from vessel entry site; line access ports sit externally; cuff to reduce line colonisation along tract; the 3 way valve in a Groshong line restricts blood backflow and air embolism	Long term administration of irritant drugs (such as chemotherapy)
Totally implantable (such as implanted port)	Internal jugular vein, subclavian vein	Long term (months to years)	Entire line and port lie subcutaneously; port accessed by non-coring needle; lower rates of CVC-BSIs compared with other central venous catheters	Long term intermittent access (for example, regular hospital admissions with poor intravenous access); administration of irritant drugs (such as chemotherapy)

CVC-BSIs=central venous catheter bloodstream infections.

Table 2| Complications of central venous catheterisation

Immediate complications		Delayed complications		
Mechanical	Thromboembolic	Mechanical	Infectious	Thromboembolic
Arterial puncture	Air embolism	Cardiac tamponade	Catheter colonisation	Catheter related thrombus
Intra-arterial placement of catheter	Wire embolism	Erosion or perforation of vessel	Catheter related bloodstream infection	Pulmonary embolism
Haemorrhage		Venous stenosis		Air embolism
Pneumothorax		Line fracture and embolism		
Haemothorax				
Arrhythmia				
Thoracic duct injury				
Cardiac tamponade				

Figures

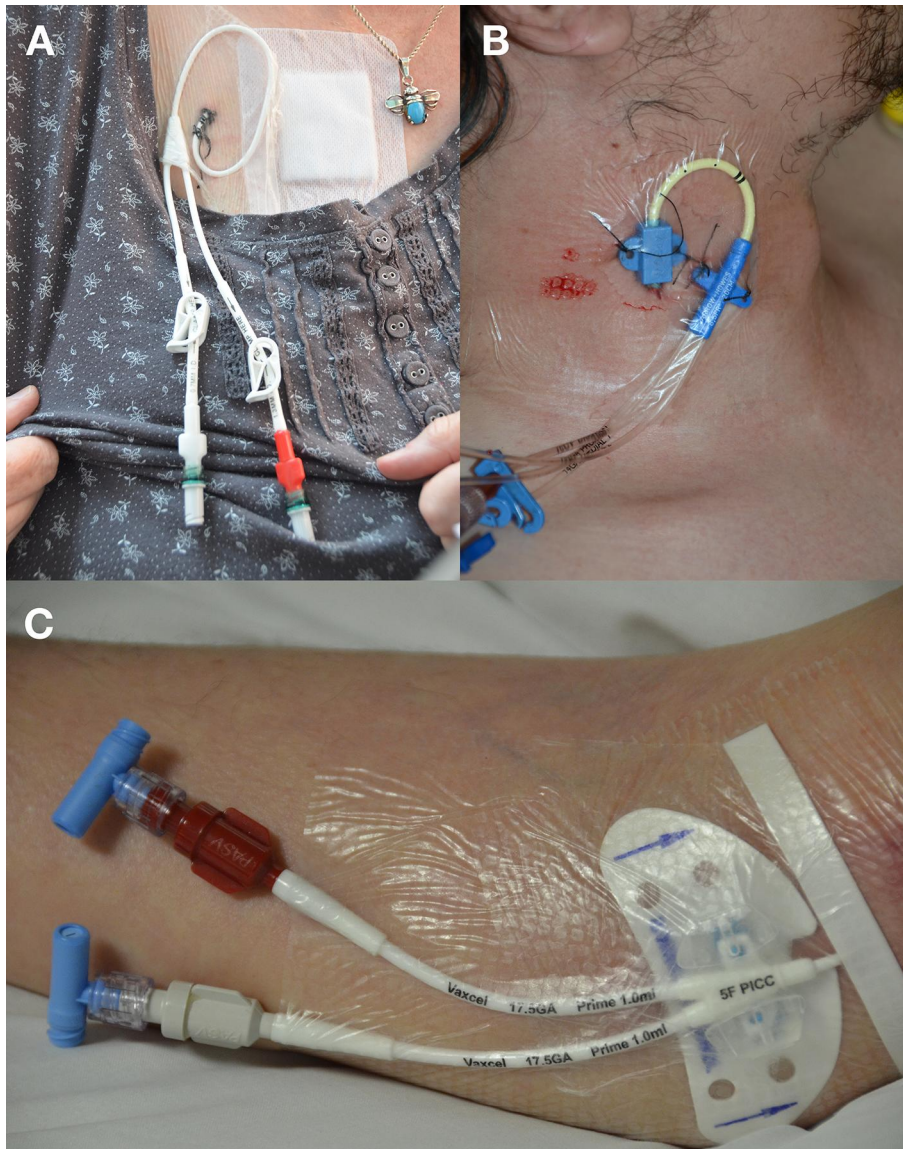


Fig 1 (A) Tunneled central venous catheter (Hickman line); (B) multi-lumen line in right internal jugular vein secured with sutures and a dressing applied; (C) peripherally inserted central catheter

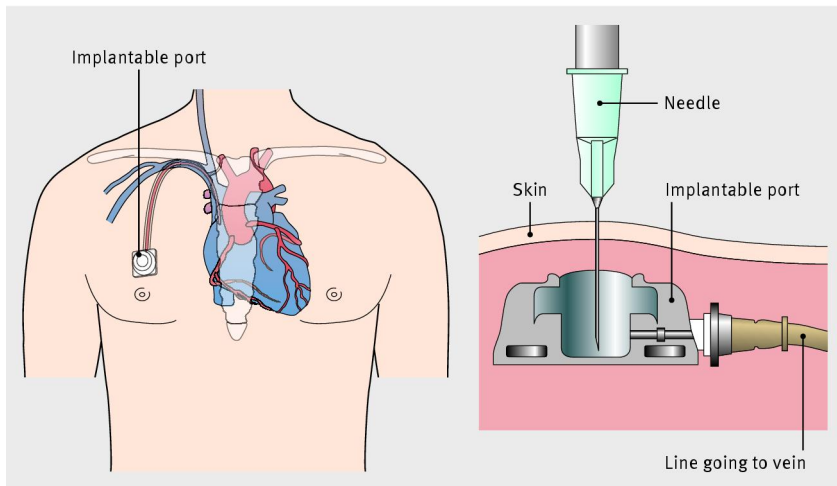


Fig 2 Illustration of a totally implantable central venous catheter

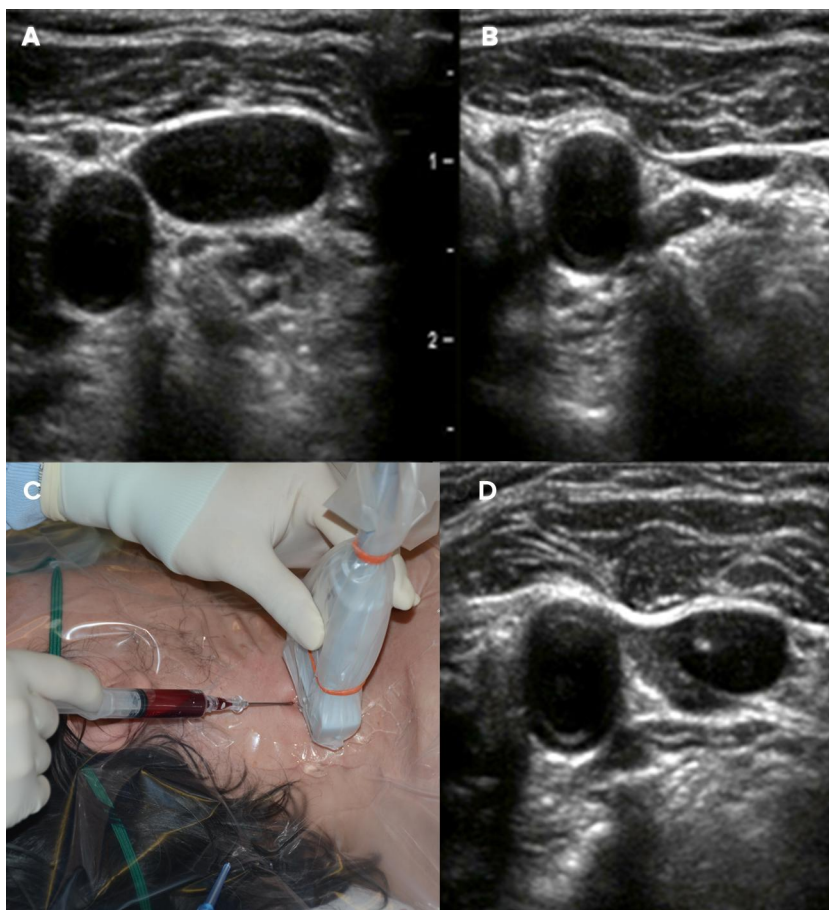


Fig 3 (A) Ultrasound image of the right internal jugular vein (no compression). (B) Ultrasound image of the right internal jugular vein compressed by the probe. (C) Insertion of needle under real time ultrasound guidance (out of plane). (D) Ultrasound image (out of plane) of needle in right internal jugular vein (echogenic (white) spot in centre of vein)